

Short Communication

SURGICAL MANAGEMENT OF TRAUMATIC INGUINAL HERNIA IN A CAT -A CASE REPORT

A.K.Sharma*¹, S. K. Singh², Bidyabhusan², Sneha kumari²

Received 13 January 2018, revised 22 November 2018

ABSTRACT: A non-descript cat of 2 years of age and weighing 5 kg was affected with long standing fibrosed inguinal hernia had sinus and discharging purulent materials as a consequence of dog bite. The cat was treated surgically by removal of fibrosed portion and herniorrhaphy done after placing the mesentery along with intestine into the abdomen. The cat made uneventful recovery without any further complication.

Key words: Cat, Dog bite, Inguinal hernia.

Traumatic abdominal wall hernias are protrusions of abdominal contents through a trauma-induced defect in the abdominal wall. Blunt trauma has been reported to be the most common cause of traumatic herniation in dogs and cats (Kraus 1990, Shaw *et al.* 2003). Information about management of long standing traumatic inguinal hernia as a result of dog bite wound in a cat is scarce.

Case history and observation

A non-descript cat of 2 years age and weighing 5 kg was presented in the department of Veterinary Surgery and Radiology with history of inguinal swelling with purulent discharge through sinus opening since last 3 months (Fig. 1). Inappetence, reluctance in the movement, dullness and depression has been noticed at frequent intervals after incidence. Heart rate, respiration rate and rectal temperature were transiently increased within normal limit during appearance of symptoms. Other haemato-biochemical parameters remained within normal physiological limits. Palpation revealed that the swelling was hard in consistency and irreducible. Keeping in view of purulent discharge and clinical signs of inappetence with change in the physiological parameters, surgical operation has been planned to remove the fibrosed portion followed by herniorrhaphy.

Treatment and discussion

The operative area was prepared aseptically. Ketamine was administered @ 20 mg/kg bwt intramuscularly

followed by induction with propofol @ 4 mg/kg bwt till the loss of pedal and jaw reflex. After that the animal was intubated with endotracheal tube of 5 mm diameter using laryngoscope. Then anaesthesia was maintained with propofol. An elliptical incision was given on the base of fibrosed portion of swelling. The tissue was separated by blunt dissection. The hernia content was intestine and intestinal mesenteries which adhered with the muscle and skin (Fig. 2). The fibrosed portion along with skin was removed (Fig. 4). The mesentery was separated carefully from the adhesion and placed in to the abdominal cavity. A hernia ring of 3 cm length and 2 cm width was noticed (Fig. 3). Herniorrhaphy was done by Mersilk (Ethicon- manufactured in India by Johnson and Johnson Ltd.) no. 2/0 using overlapping suturing pattern. Rest of abdominal wound was sutured as routine surgical procedure. The cat was treated with intramuscular administration of ceftriaxone @ 25 mg/kg b.wt. for 5 days and Meloxicam @ 0.5 mg/kg b.wt. for 2 days as antiinflammatory agent. The case was again presented on day 7 with self- mutilation of wound and removal of skin suture. The muscle suture healed properly with appearance of healthy tissue and increased appetite and activity. Skin resuturing was done under general anaesthesia. The cat was recovered without further any complication.

The irreducible hernia with adhered viscera needs to be corrected without delay as that will cause necrosis of intestine and as consequence unavoidable death of animal

¹Assistant Professor(SS), ²M.V.Sc Scholar, Dept. of Surgery and Radiology, College of Veterinary Science and Animal Husbandry, Birsa Agricultural University, Kanke, Ranchi, India.

*Corresponding author. e-mail: arsham10@rediffmail.com

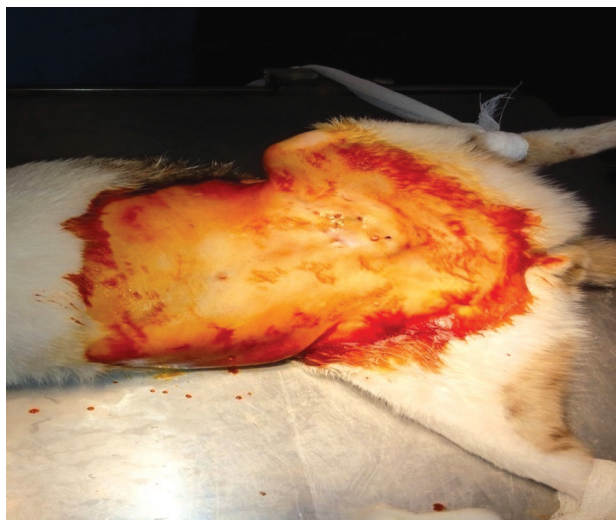

Fig. 1. Photograph showing inguinal hernia with fibrosed swelling and sinus opening (Arrow).

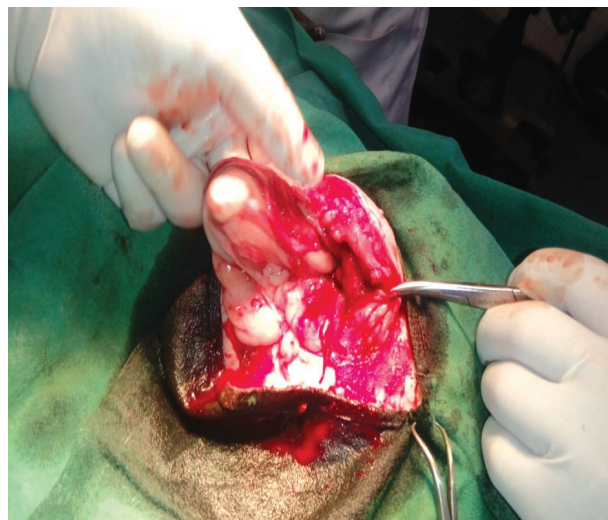


Fig. 2. Photograph showing adhesion of mesentery with intestine as hernial content.

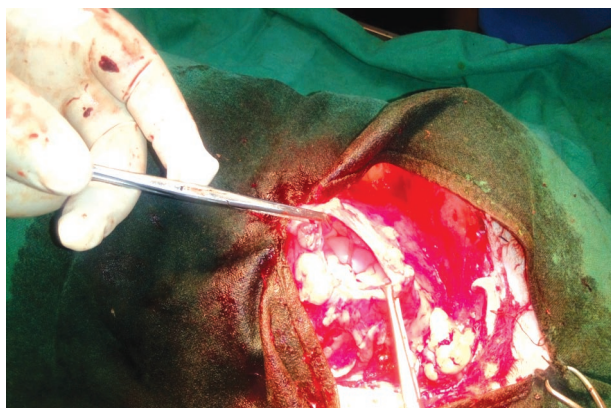


Fig. 3. Photograph showing hernial ring measuring 3 cm length and 2 cm width.

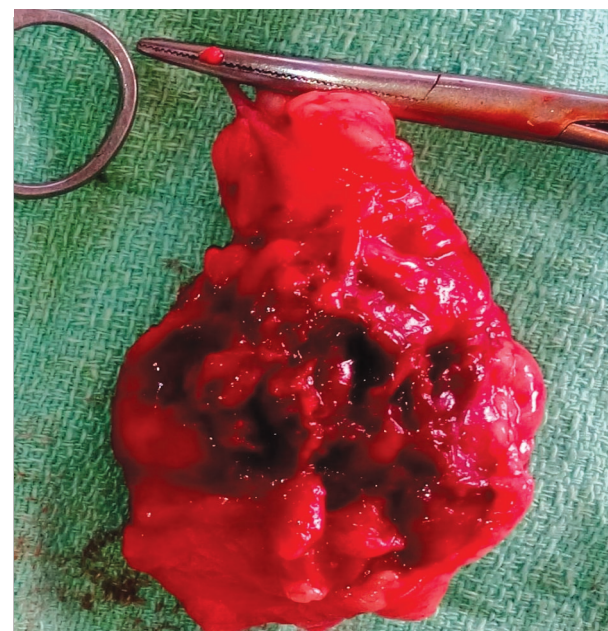


Fig. 4. Photograph showing removed fibrosed portion along with sinus opening.

will result. Similar reports have been documented by many researchers (Neville-Towle and Sakals 2015, Rizk and Samy 2016).

It is concluded that the cat with inguinal hernia as a consequence of dog bite injury complicated with purulent sinus discharge with adhesion and fibrosis can be treated by surgical intervention with successful outcome. However, it is better to manage such type of condition as early as possible to prevent any complications.

REFERENCES

Kraus KH (1990) Traumatic abdominal hernias. Cited in: Bojrab M, Birchard S, Tomlinson J, editors. Current techniques in small animal surgery. 3rd edn. Philadelphia: Lea and Febiger. 449-453.

Neville-Towle J, Sakals S (2015) Urinary bladder herniation through a caudoventral abdominal wall defect in a mature cat. *Can Vet J* 56(9): 934-936.

Rizk A, Samy A (2016) Diagnosis and surgical repair of entero-cystocele in a cat. *Open Vet J* 6(3): 162-164.

Shaw SR, Rozanski EA, Rush JE (2003) Traumatic body wall herniation in 36 dogs and cats. *J Am Anim Hosp Assoc* 39: 35-46.

Cite this article as: Sharma AK, Singh SK, Bidyabhusan, Sneha kumari (2018) Surgical management of traumatic inguinal hernia in a cat - a case report. *Explor Anim Med Res* 8(2): 220-221.