

Short Communication

HEPATOCELLULAR CARCINOMA IN A DOG - A CASE REPORT

Shivaji Bhattacharya, B. Dutta, J. Mukherjee, G. Chakraborty and Malay Mitra

Hepatocellular carcinoma (HCC) are the most common primary liver tumor in male dogs (The Merck Veterinary Manual 2010) and it is not uncommon in sniffer dog. These neoplasms typically affect younger dogs, more than two-thirds of the dogs are less than 10 years old (Patnaik *et al.* 2005). It occurs frequently in mammalian hosts including human (Bertino 1996). Several workers were reported hepatocellular carcinoma in different canine species (Patnaik *et al.* 1980, Evans 1987, Liptak *et al.* 2004, Sterczer *et al.* 2011).

A carcass of sniffer Labrador dog of Central Industrial Security Force, Kolkata Port Trust, aged about three years and six months was brought to Disease Investigation Laboratory, Institute of Animal Health & Veterinary Biologicals, Kolkata, India for postmortem examination to ascertain the cause of death. The dog was suffering in chronic hepatic disorders for last few months with the history of anorexia, lethargy, weakness, inactivity, apathy, weight loss,

polydipsia, vomition, abdominal pain and ascites. It was finally unfit for training programme and duty before death.

Haematological and biochemical parameters primarily revealed Total Leucocytic Count (TLC) 6,800 cu. mm, Differential Leucocytic Count (DLC) (Neutrophil 84%, Lymphocyte 13%, Monocyte 1%, Eosinophil 2%, Basophil 0%), Haemoglobin 10.4 gm%, Serum urea 39.80 mg/dl, Blood Urea Nitrogen (BUN) 19.00 mg/dl, Serum creatinine 1.55 mg/dl, SGPT/ALT 83.10 u/l, SGPT/ASL 84.60 u/l, Serum potassium 4.60 mcg/l, Total Serum protein 6.80 gm% (Albumin 3.40 gm%, Globulin 3.40 gm%, Albumin Globulin ratio 1 : 1). The Thyroid function test by Chemiluminescence assay (CLIA) showed Total triiodothyroxin (T₃) 1.44 ng/ml, Total thyroxin (T₄) 10.87 µg/dl, Thyroid stimulating hormone (TSH) 0.34 ng/ml. Examination of aspirated peritoneal fluid revealed presence of blood cells predominantly lymphocytes with nucleated total cell 780/cu. mm, Sugar

*Institute of Animal Health & Veterinary Biologicals,
37, Belgachia Road, Kolkata - 700037, West Bengal, India.*

Hepatocellular Carcinoma in a Dog

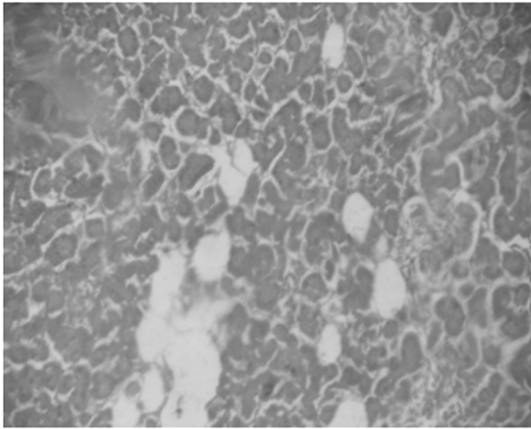


Fig.1: Irregular masses of enlarged hepatocytes with proliferation of reticular fibers showed pseudo-lobulation(10X)

107.0 mg/dl, Total Protein 5.6 gm/dl, Chloride 89.6 mcg / l . The smear of ascitic fluid showed presence of inflammatory and sheets of reactive mesothelial cells.

Ultrasonography of whole abdomen revealed overall gross ascites with a small right sided pleural effusion. Hepatic veins were apathy and dilated. Gall bladder was

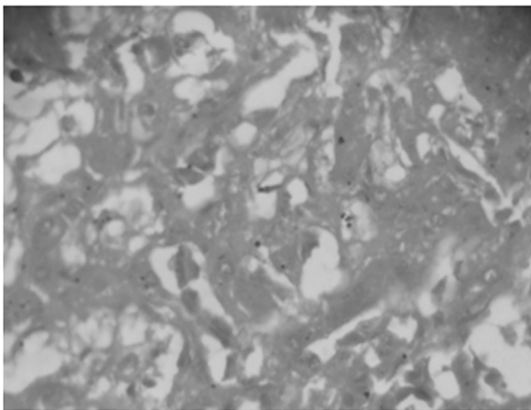


Fig.3: Well developed proliferating hepatocytes with large nuclei and few mitotic figures (40X) .

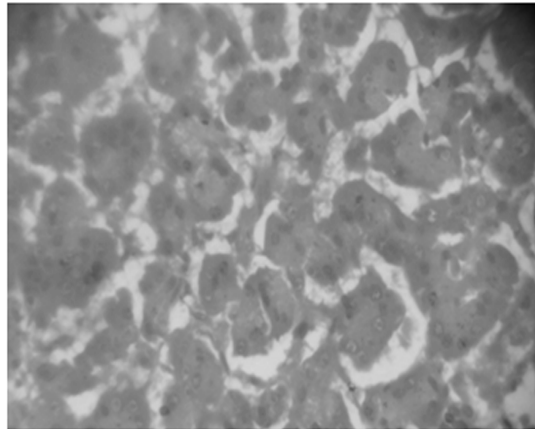


Fig.2: The large hepatocytes showed few mitotic figures with proliferation of reticular fibers there in. Some places the nuclei of few hepatocytes showing hyper-chromasia with vesicular cytoplasm indicating irregular cell division(40X).

distended and walls were thin, measured 2 mm at the porta hepatis. Inferior vena cava (IVC) behind the liver was distended.

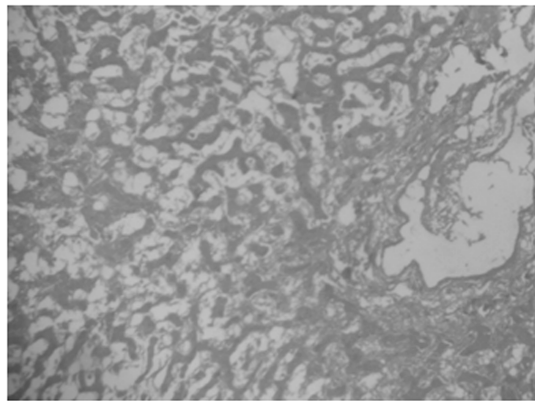


Fig.4: Periportal fibrosis and perivascular proliferation of bile duct, hepatic artery and portal vein. Necrosis of surrounding hepatocytes due to pressure of irregularly scattered hepatocytes and reticular proliferation (10X).

Primarily considered ascites of inflammatory or neoplastic etiology.

The dog was treated for last few months with several medicines without showing any improvement and that gradually became off-fed, reluctant to move, unfit for any work and finally died.

Postmortem examination revealed presence of moderate amount of sero-sanguinous fluid in thoracic cavity and hyperemic thoracic wall in general. Lower part of trachea and broncho-tracheal portion were anastomosed with oesophagus, blood vessels, nerve along with surrounding tissues adhered with spine. Trachea was mild haemorrhagic. Lower part of trachea and broncho-tracheal portion were anastomosed. Right lung was partly solidified, suppurative and haemorrhagic. Left lung was pneumonic, cyanosed and consolidated. Heart was hypertrophic and chambers were filled with clotted blood. Pericardium found congested. Diaphragm was severely congested. Spleen was enlarged and anaemic. Liver was hypertrophic, cirrhotic along with perihepatitis. Stomach was empty. Pancreas was atrophic and anaemic. Intestine was partly haemorrhagic. Mesenteric lymph nodes were enlarged and haemorrhagic. Kidneys were hypertrophic and congestion in cortex. Urinary bladder was thickened with scanty haemorrhages in mucosa. A large amount of dark straw coloured ascitic fluid was revealed in abdominal cavity, which was collected aseptically and *Escherichia coli* was isolated.

Hepato-cellular carcinoma was detected in histopathological examination. The architectural details showed irregular masses of enlarged hepatocytes with proliferation of reticular fibers given pseudo-lobulation

(Fig.1). The large hepatocytes showed few mitotic figures with proliferation of reticular fibers there in. In some places the nuclei of few hepatocytes showed hyper-chromasia with vesicular cytoplasm indicating irregular cell division (Fig.2). The section depicted a well developed proliferating hepatocytes with large nuclei and few mitotic figures (Fig.3). Periportal fibrosis and perivascular proliferation of bile duct, hepatic artery and portal vein were evident. The surrounding hepatocytes were almost necrosed due to pressure of irregularly scattered hepatocytes and reticular proliferation (Fig.4). The liver cells were anaplastic, arranged in trabecular or acinar pattern, mitosis and enlarged nuclei commonly seen, which corroborate with the finding of Vegad (1995). The trabecular growth pattern was 2-8 cells wide layer of tumour cells, which showed similarities with the findings of Mohan (1953). Tumour cells were composed of nest and end to malignant appearing hepatocytes separated by dense bundle of collagen, which corroborate with the findings of Cotran *et al.* (1994). Suppurative pneumonia and myocarditis were revealed during histopathological examination of lungs and heart muscles respectively. Considering all, it was finally concluded that the dog was died due to multi-organ failure as a consequence of hepato-cellular carcinoma.

ACKNOWLEDGEMENT

Authors are thankful to the Director of Animal Husbandry & Veterinary Services, West Bengal for providing necessary facilities for this work and Central Industrial Security Force, Kolkata Port Trust, Kolkata for providing materials.

REFERENCES

- Bertino JR.(1996).** Encyclopedia of Cancer. Vol.II. Academica Press. Inc. California. USA. p.808-809.
- Cotran RS, Kumar V and Robbins SL (1994).** Robbin's Pathologic basis of disease. 5th edn. Prism Book Pvt. Ltd. Bangalore. p.879-882.
- Evans SM.(1987).** The radiographic appearance of primary liver neoplasia in dogs. *Vet Radiol.* 28: 192-196.
- Liptak JM, Dernell WS, Monnet E, Powers BE, Bachand AM, Kenney JG and Withrow SJ.(2004).** Massive hepatocellular carcinoma in dogs: 48 cases (1992-2002). *J. Am. Vet. Med. Assoc.* 225: 1225-1230.
- Mohan H. (1953).** Textbook of Pathology. 2nd edn. Jay Pee Brothers. New Delhi. p.636-638.
- Patnaik AK, Hurvitz AI and Lieberman PH.(1980).** Canine hepatic neoplasms : a clinicopathologic study. *Vet Pathol.* 17: 553-564.
- Patnaik AK, Newman SJ and Scase T.(2005).** Canine hepatic neuroendocrine carcinoma: an immuno-histochemical and electron microscopic study. *Vet Pathol.* 42: 140-146.
- Sterczer A, Nemeth T, Mandoki M, Galfi P and Jakab C.(2011).** A case of synchronous hepatocellular carcinoma and aortic body chemodectoma in a dog - pathological case report. *Acta. Vet. Hung.* 59(1): 113-121.
- The Merck Veterinary Manual. (2010).** 10th edn. Merck Sharp & Dohme Corp. Merck & Co. Inc. USA.
- Vegad JL.(1995).** Textbook of Veterinary General Pathology. Vikash Publishing House Pvt. Ltd. New Delhi. p.284-285.

With Best Compliments from :-



H. L. PHARMACEUTICALS

DISTRIBUTORS & WHOLE SALERS

105, Deshbandhu Road (West)

1st. Floor, Kolkata - 700 035



Sunil Das

Mobile : 9831480996, 9804444864, 9330805352

Tel Fax : 033-25789268

Email : hlp.mkt@rediffmail.com