

Short Communication

**SUCCESSFUL MANAGEMENT OF CERVICO-VAGINAL PROLAPSE IN A MURRAH
BUFFALO - A CASE REPORT**

Amit Sharma, Akshay Sharma, Madhumeet Singh, Pravesh Kumar, Pinki Saini, Anupama Thakur, Aanchal Sharma, Amit Kashyap, Aaquib Majid Jan, Shriya Gupta*

Received 02 August 2017, revised 10 November 2017

ABSTRACT: A Murrah crossbred buffalo was presented with a history of postpartum cervico-vaginal prolapse and incomplete cervical lacerations. The lacerated area was corrected by applying simple interrupted sutures. The prolapsed mass was reduced and replaced back to its normal position. The buffalo recovered following application of Buhner's suture and standard treatment protocol.

Key words: Buhner's suture, Murrah crossbred buffalo, Cervico-vaginal prolapse, Cervical lacerations.

Prolapse is falling down or slipping of a body part from its usual position. Prolapse of cervix and vagina (CVP) is common obstetrical problem which adversely affects productive and reproductive performance by affecting postpartum return to estrus, conception rate and calving interval. Cervico-vaginal prolapse usually involve protrusion of the portion of the floor, lateral walls and roof of vagina through vulva along with the cervix and uterus, moving caudally (Roberts 1971). The present communication envisages the successful treatment of postpartum cervico-vaginal prolapse with an incomplete cervical tear.

Case details

A primiparous Murrah crossbred buffalo was presented in Teaching Veterinary Clinical Complex (TVCC), CSKHPKV, India with a history of cervico-vaginal prolapse from last 2 days. Further anamnesis revealed that buffalo calved 10 days ago and manual traction was applied during per vaginal delivery of fetus. Physical examination revealed the prolapsed cervix and vagina with lacerations on dorsal and lateral walls of cervix (Fig. 1). Buffalo was continuously straining and did not take feed and water from last 2 days. However, rectal temperature (102.4°F) and heart rate (83 bpm) was normal. Based on history and physical examination, the case was diagnosed as postpartum cervico-vaginal prolapse with cervical lacerations. Pre-operative therapy was advocated with intravenous administration of Dexamethasone 40 mg (Zidex®, Laborate Pharma, India), Haemostypticum 20 ml, total dose (Revici®, Kee Pharma,

India) intramuscularly and 5 ml Lignocaine hydrochloride 2% (LOX®, Neon Labs, India) as an epidural anesthetic to reduce straining. Then, the prolapsed mass was cleaned with running tap water and Potassium permanganate solution (1:1000 dilution) followed by application of icepacks to reduce edema and volume of the mass. Catheterization of the urinary bladder was done to remove urine. Then, the cervical lacerations were sutured using simple interrupted suture (Chromic catgut no. 2). The prolapsed mass was again washed with cold water and lubricated with Lignocaine jelly (Lignox®, Neon Labs, India) and Soframycin ointment (Soframycin®, Sanofi, India). Constant pressure was applied to repose the prolapsed mass into its normal anatomical position. Just to avoid recurrence, Buhner's suture was applied (Fig. 2). As a part of post-operative therapy, buffalo was administered Streptopenicillin @ 12.5 mg/kg b. wt. once a day (DCR-S®, Zydus AHL, India), Meloxicam @ 0.2mg/kg IM (Melonex®, Intas Pharma, India) for 5 days and Inj. Oxytocin 100 I.U., total dose (Evatocin®, Neon Labs, India) intramuscularly. The fluid therapy was provided with Ringer's Lactate (2 litres), Normal saline (2 litres), Calcium magnesium borogluconate at a dose of 1.5 ml/kg body wt. (Mifex®, Novartis Pharma, India) by slow intravenous route along with Belamyl @ 10 ml intramuscularly a.d for 5 days. Cold fomentation and vaginal smearing with Zinc oxide, Soframycin ointment and Lignocaine jelly was done daily for 3 days. To reduce the chances of urinary tract infection, animal was also given powder Sodium acid phosphate (30g) orally followed by Hexamine (15g) after 30 minutes orally

Department of Veterinary Gynecology and Obstetrics, College of Veterinary and Animal Sciences, Himachal Pradesh Agricultural University, Palampur, India.

**Corresponding author. e- mail: 1994shriyagupta@gmail.com*

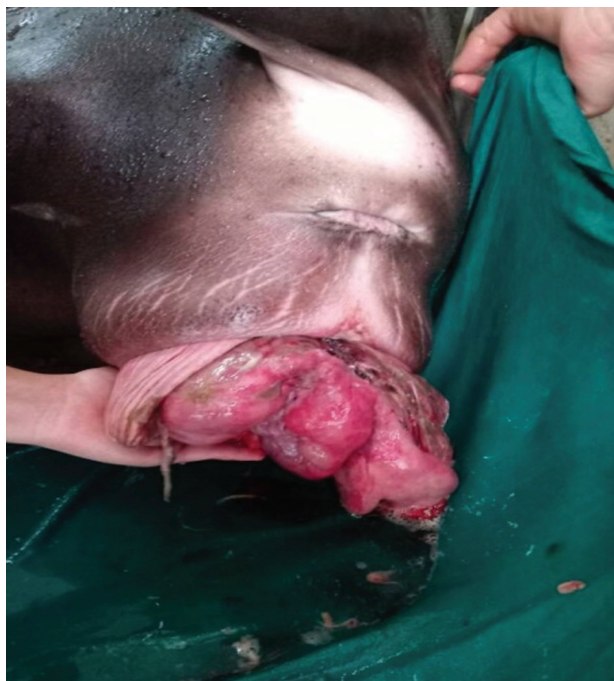

Fig. 1. Prolapsed mass with cervical tear.

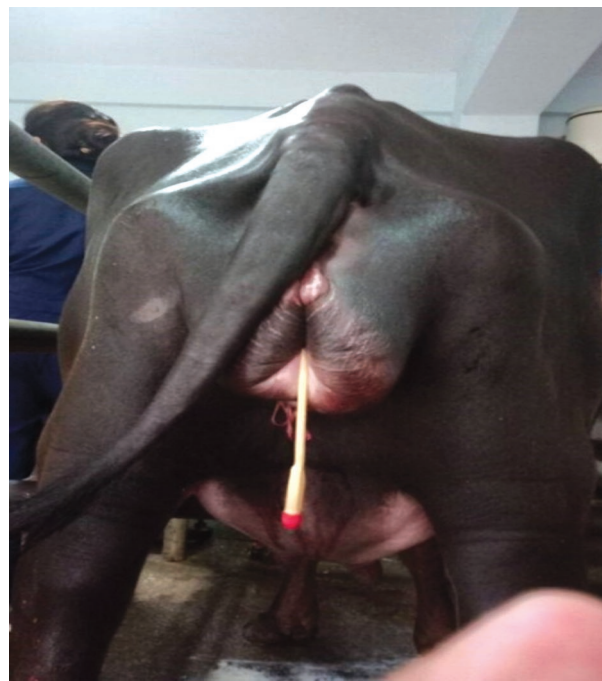


Fig. 2. After management of cervico-vaginal prolapse.

for 6 days. Reduced straining and normal feeding was observed after treatment.

Post-partum prolapse of genital organs accounts for about 22 percent of total reproductive disorders in buffaloes (Pandit *et al.* 1982). Occurrence of post-partum cervico-vaginal prolapse is mainly due to severe straining in response to vaginal trauma or infection which may be a sequel of dystocia. Vaginal contusion at parturition, followed by *Fusobacterium necrophorum* infection exerts a high degree of irritation with frequent expulsive efforts (Arthur 2001). Lack of myometrial tone and increased intra-abdominal pressure may also lead to CVP (Kapadia *et al.* 2015). Higher incidence of non-dilatation of the cervix is also accompanied by cervical lacerations following per vaginal delivery (Pascale *et al.* 2008). Ahmed *et al.* (2005) and Akhtar *et al.* (2008) reported that lower calcium, phosphorus and higher magnesium concentration was observed in buffaloes suffering from vaginal prolapse. Cervico-vaginal prolapse is more common than uterine prolapse and it looks like a pink mass of tissue having a size of volleyball (Patil *et al.* 2014).

REFERENCES

Ahmed S, Ahmad I, Lodhi LA, Ahmad N, Samad HA (2005) Clinical, haematological and serum macro mineral contents in buffaloes with genital prolapse. *Pak Vet J* 25: 167-170.

Akhtar MS, Lodhi LA, Ahmad I, Qureshi ZI, Muhammad G (2008) Serum concentrations of calcium, phosphorus and magnesium in pregnant Nili-ravi buffaloes with or without vaginal prolapse in irrigated and rain fed areas of Punjab, Pakistan. *Pak Vet J* 28(3): 107-110.

Arthur GH (2001) Arthur's Veterinary Reproduction and obstetrics, 8th edn. Edited by Noakes DE, Parkinson TJ and Gary CW, Elsevier's, London.

Kapadiya PS, Chauhan PM, Nakhshi HC, Sharma VK, Sutaria TV (2015) Recurrent post-partum uterine prolapse in a primiparous Mehsana buffalo- A case report. *J Livestock Sci* 6: 109-112.

Pandit RK, Gupta SK, Pattabiraman SR (1982) A clinical study of vagina and uterus in buffaloes. *Indian Vet J* 59: 975-980.

Pascale A, Warnick LD, DesCoteaux L, Bouchard E (2008) A study of 55 field cases of uterine torsion in dairy cattle. *Can Vet J* 49(4): 366-372.

Patil AD, Narwade PS, Raghuwanshi DS (2014) Management of prepartum cervico-vaginal prolapse in 37 dairy animals. *Intas Polivet* 15(2): 459-460.

Robert's SJ (1971) Diseases of the puerperal period. In *Veterinary Obstetrics & Genital Diseases*. CBS Publishers & Distributors, Delhi, India. 303-313.

*Cite this article as: Sharma A, Sharma A, Singh M, Kumar P, Saini P, Thakur A, Sharma A, Kashyap A, Majid Jan A, Gupta S (2017) Successful management of cervico-vaginal prolapse in a Murrah buffalo - a case report . *Explor Anim Med Res* 7(2): 225-226