

## Short Communication

# SURGICAL MANAGEMENT OF NECK TUMOURS IN DOGS: CASE REPORTS

Jayakrushna Das<sup>1\*</sup>, Snehasis Pradhan<sup>1</sup>, Srinivas Sathapathy<sup>2</sup>

*Received 10 August 2016, revised 14 November 2016*

**ABSTRACT:** The present study was conducted on two dogs, one pug and one mongrel presented with the history of swelling at the base of neck. In one of the cases there was ulceration of the skin around the enlarged mass and in the second case there was gradual increase in size of the mass along with bending of neck to one side and reduced appetite. Further, the physical and radiographical examinations were conducted that confirmed the occurrence of tumour in both the cases. Under physical restraint and general anaesthesia the excision of the tumour mass was done along with the proper control of haemorrhage. Both the cases recovered well without any critical symptoms there of up to one year after surgery.

**Keywords:** Neck tumour, Dog, Surgical management.

A tumour (neoplasm) is caused by a purposeless multiplication of living cells and it is different from inflammatory hyperplasia (Venugopalan 2013). It is more common in carnivore as compared to other animals (Todorova 2006). Old animals are affected more commonly than younger ones. It is classified clinically as benign, malignant, solitary, and multiple tumours. Benign tumours remain local, and do not recur after excision. They are comparatively slow in growth, the skin does not adhere to them and do not ulcerate on their surface. Malignant tumours develop rapidly and give rise to secondary tumours in

their vicinity and at a distance, the neoplastic elements being carried by the lymph or blood stream (metastasis). They recur even after excision. The skin is usually adhered to their surface and is frequently ulcerated at their level. Carcinogens may be present in food grains as unrecognised plant contaminants (*e.g.*, *Senecio* sp. and *Crotolaria* sp.) or as spoilage moulds on feeds (*e.g.*, aflatoxin) and they act initially by transforming the cell after which the growth is irreversible even after removal of the carcinogenic agent (Tyagi and Singh 2013).

In this paper two cases of affected dogs of one pup of Pug and other of Mongrel were

---

<sup>1</sup>Department of Veterinary Surgery and Radiology, <sup>2</sup>Department of Anatomy and Histology, College of Veterinary Science & Animal Husbandry, Orissa University of Agriculture and Technology, Bhubaneswar-751 003, Odisha, India.

\*Corresponding author. e- mail: drjohndasjajpur@gmail.com

presented with large growing mass near neck region. As the growths were non-fluctuating and hard to touch, so suspected for neoplastic growth and decision of surgical excision of mass was taken to relief pain and sufferings of animal.

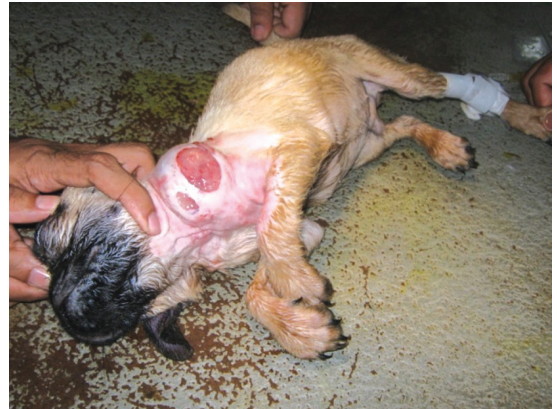### Case I

One Pug pup of 40 days old was presented with a large swelling at the left lateral side of neck with ulceration of skin covering the mass, rise of temperature, bending of neck towards opposite side, profuse salivation and inappetance. Physical examination revealed a non fluctuating mass having its stump attached to the Brachiocephalicus muscle, the skin covering the mass was ulcerated. Then the radiographical examination revealed radio dense substance around the region. From physical and radiographical examination, the condition was tentatively suspected to be a neoplastic growth, so decision of surgical excision of the mass was taken to relief pain and sufferings of the animal. The owner was advised to keep the animal in fasting for 6 hours. The animal was restrained and anaesthetized using atropine @ 0.04mg/kg body weight (b.wt.), xylazine @ 0.5mg/kg b.wt. and ketamine @ 3mg/kg b.wt I/M along with fluid therapy. The site was routinely cleaned. The mass was hold properly and incision was given on it. Then the skin and subcutaneous layers was separated with blunt dissection and the tumour was exposed. The blood vessels supplied to the stump was secured carefully with proper ligation and trans-fixation, then the tumour was excised. Care was taken for jugular vein, oesophagus and laryngeal nerve to prevent injury during the excision. The muscle was sutured with Vicryl no. 1/0 suture in continuous Pattern. The skin was sutured with nylon in

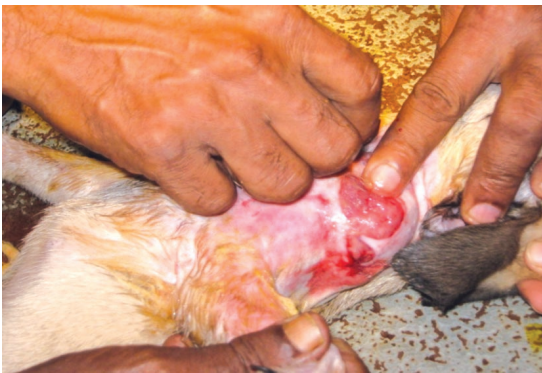simple interrupted pattern. Then antiseptic solution was applied and ointment Mupirocin (Staphban<sup>a</sup>) was applied over it. The animal was given Ceftriaxone sodium @ 10mg/kg b. wt. for 5 days and meloxicam @ 0.02mg/kg b.wt. for 3 days respectively.

### Case 2

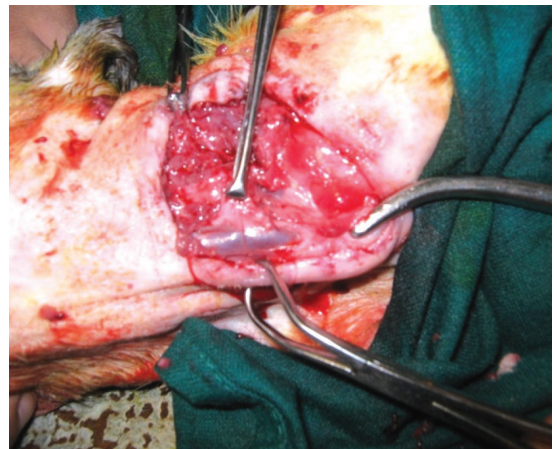
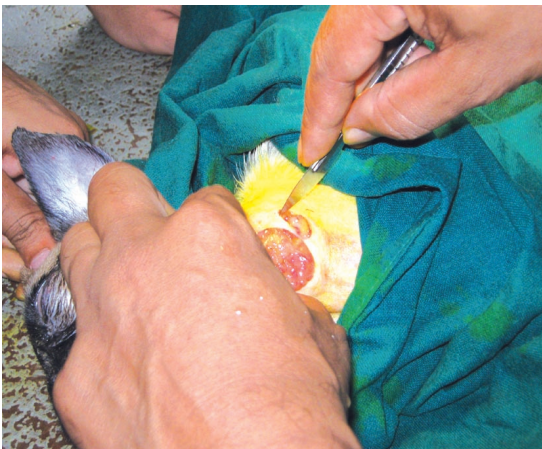One mongrel dog of 2 years old was presented at the Department of Veterinary Surgery and Radiology with complaint of a large pendulous growth on the mid ventral side of neck region at sterno-thyrohyoideus muscle with ulceration over it, anorexia, fever, dullness, bending of neck to opposite side. The radiographic study revealed radio-dense/opaque mass. The mass was not fluctuating and needle aspiration revealed no fluid inside it. Hence the condition was suspected for any neoplastic growth/ tumour. The animal was fasted for 12 hours and anaesthetized using atropine @ 0.04mg/kg body weight (b.wt.), xylazine @ 0.5 mg/kg b.wt. and ketamine @ 5 mg/kg b.wt I/M along with fluid therapy. The site was shaved routinely cleaned and draped properly. The pendulous mass was hold and ventral midline incision was given on it. Then the skin and subcutaneous tissues were separated with blunt incision and the tumour was exposed. Blood vessels supplied to the stump were ligated and the growth was excised. The site was cleaned with normal saline solution. The muscle was sutured with Vicryl no. 1/0 suture. The extra pendulous skin was excised and sutured with nylon in interrupted pattern. Then Povidone iodine solution was applied and Mupirocin ointment (Staphban, Sava vet pharmaceuticals) was applied over it. The animal was given ceftriaxone @ 10mg/kg b. wt. and meloxicam @ 0.02mg/kg b.wt. and the same was continued



**Fig. 1 & 2. Showing the site of tumour in two dogs.**



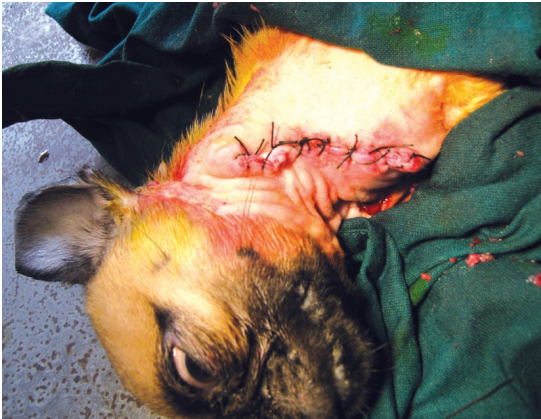**Fig. 3. Showing ulceration of skin over the tumour.**



**Fig. 4 & 5. Showing the excision of tumour mass.**

for 5 days as postoperative measure.

Due to prompt diagnosis of the condition with immediate attempt of surgical treatment could help to reduce the pain, discomfort and sufferings of the animal. The clinic-lab investigation of blood revealed the value of haemoglobin, TLC, TRBC and DC were within the normal physiological range along with negative for microfilaria organism. The complete removal of the tumour mass was done to prevent the reoccurrence of the condition.



**Fig. 6. Showing sutured skin after removal of the mass.**

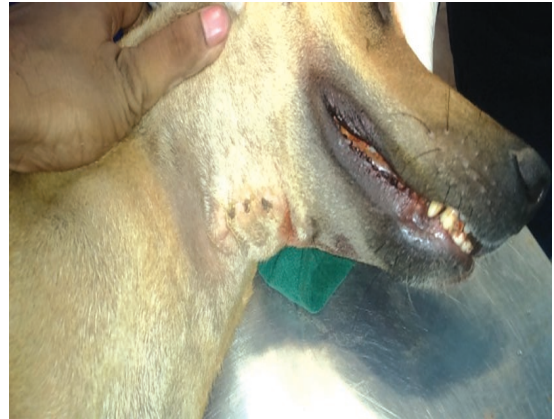The standard surgical approach for the head and neck cancers is excision of the primary lesion, followed by sampling of the periphery of the resultant defect with multiple intra-operative frozen sections to ensure complete removal of the tumour. The most important prognostic factor in patients with head and neck squamous cell carcinoma is the completeness of surgical removal of the tumour (Snow 1989).

### ACKNOWLEDGEMENT

The Authors are thankful to the faculties of Dept. of Anatomy and Histology, C.V.Sc. & A.H., OUAT, Bhubaneswar for their cooperation and guidance throughout the surgery.

### REFERENCES

Gandour-Edwards RF, Donald PJ, Lie JT (1993) Clinical utility of intraoperative frozen section



**Fig. 7. Showing the site after 21 days of operative procedure.**

diagnosis in head and neck surgery: a quality assurance perspective. *Head and Neck Surg* 15: 373-376.

Snow GB (1989) Evaluation and staging of the patients with head and neck cancer. In: Myers EN and Suen JY, eds. *Cancer of the head and neck*. 2<sup>nd</sup> edn., New York: Churchill Livingstone. 17-38.

Tyagi RPS, Singh J (2013) *A Text Book of Ruminant Surgery*. CBS Publishers and Distributors Pvt. Ltd., New Delhi. 412.

Todorova I (2006) Prevalence and etiology of the most common malignant tumours in dogs and cats. *Bulgarian J Vet Medic* 9(2): 85-98.

Venugopalan A (2013) *Essentials of Veterinary Surgery*, 8<sup>th</sup> edn., Oxford and IBH Publishing Company Pvt. Ltd., New Delhi. 82.

**\*Cite this article as:** Das J, Pradhan S, Sathapathy S (2016) Surgical management of neck tumours in dogs: case reports. *Explor Anim Med Res* 6(2): 254-257.